

Arrhythmic competitive athletes with apparently “intact heart”

(Ital Heart J 2004; 5 (Suppl 1): 88S-96S)

© 2004 CEPI Srl

SUDDEN CARDIAC DEATH AND APPARENTLY INTACT HEART: PATHOLOGICAL EXAMINATION

Gaetano Thiene

Institute of Pathology, University of Padua Medical School, Padua, Italy

Most of sudden deaths find an easy explanation at *postmortem*, revealing gross structural abnormalities accounting for abrupt outcome. This is the case for cerebral sudden death due to apoplexy or subarachnoid hemorrhage or respiratory death due to bronchospasm with acute emphysema. In case of cardiovascular deaths, a mechanical cause is quite evident: pulmonary embolism, hemopericardium, hemothorax or hemoretroperitoneum due to aortic rupture¹.

Even in case of arrhythmic death, the cause may be easily detected at naked eye: asymmetrical septal hypertrophy in hypertrophic cardiomyopathy, transmural fibrofatty infiltration in arrhythmogenic right ventricular cardiomyopathy/dysplasia, congenital (anomalous origin and cause) or acquired coronary artery disease (obstructive atherosclerosis, with or without thrombosis, dissecting hematoma, thromboembolism), coarse mitral valve prolapse, postoperative congenital heart disease (tetralogy of Fallot, atrial switched transposition of the great arteries, etc.).

It has been recently calculated that in nearly 70% of cases, the puzzle of sudden cardiac death may be solved at *postmortem* by simple gross examination (Table I)^{1,2}.

There are cases, however, in which, after excluding extracardiac or mechanical cardiovascular causes of death or gross substrates explaining ominous rhythm disturbances, the heart appears normal at gross examination and nonetheless the mode of cardiac arrest is by exclusion presumed to be arrhythmic. In this setting, histological exam-

ination is mandatory to rule out microscopic substrates, otherwise undetectable. This is the case of myocarditis, which may stop the heart through a ventricular fibrillation even in the absence of cardiac dilation or pump failure; molecular pathology techniques like polymerase chain reaction and reverse transcriptase-polymerase chain reaction, are deemed necessary to establish viral etiology³. The diagnosis of hypertrophic cardiomyopathy without hypertrophy is feasible only through evidence of myocardial disarray at light microscope. Some forms of segmental arrhythmogenic right ventricular cardiomyopathy can also be discovered only with a glance at microscope^{4,5}.

Abnormalities of the conduction system are classical subtle morphologic substrates of cardiac arrest in a grossly intact heart, and may be documented histologically only through a thorough, time-consuming investigation requiring serial section techniques⁶. This is the case for instance of Wolff-Parkinson-White syndrome, in which also all the atrioventricular rings have to be serially cut and stained⁷. Ventricular preexcitation is the smallest (microscopic) congenital heart disease (no more than 100-200 μ thick), clearly under the eye resolution. Enhanced atrioventricular conduction may find a microscopic explanation at the level of the atrioventricular specialized conduction axis, due to either hyperplasia of the atrioventricular node or to atriohisian accessory bundle, bypassing the area of delay of the atrioventricular node^{3,4}. Disruption of the atrioventricular node, His bundle and bundle branches, by impairing the continuity of the specialized conducting tissues, may be a substrate of atrioventricular block and cardiac arrest with asystole. Clearly, in the absence of an ECG, proving the existence of native atrioventricular conduction abnormalities, is quite speculative to ascribe functional life-threatening arrhythmic disturbances to subtle, questionable histologic abnormalities.

Table I. Gross pathologic features in 273 young sudden cardiac death victims.

Abnormal hearts	197 (72%)
Obstructive coronary atherosclerosis	54 (27%)
Valve disease	31 (16%)
Non-atherosclerotic coronary artery disease	28 (14%)
Arrhythmogenic right ventricular cardiomyopathy	27 (13%)
Hypertrophic cardiomyopathy	18 (9%)
Aortic rupture	13 (7%)
Dilated cardiomyopathy	12 (6%)
Postoperative congenital heart disease	5 (2.5%)
Pulmonary thromboembolisms	4 (2%)
Others	5 (2.5%)
Apparently normal hearts	76 (28%)
Total	273

From Corrado et al.², modified.

Thus, a thorough histological examination of the heart with inherent clinico-pathologic correlations may add another 20-25% of probability to find a plausible explanation of sudden cardiac death. Another 5-10% of sudden arrhythmic cardiac deaths, especially sudden deaths in the young, remain unexplained both at macro- and microscopic levels (Fig. 1). These deaths, also known as *mors sine materia*, were in the past known as "idiopathic ventricular fibrillation" since the arrhythmogenic mechanism was unknown or could not be ascribed to a substrate: long QT syndrome, Brugada syndrome, and catecholaminergic polymorphic ventricular tachycardia⁸⁻¹⁰. Whereas long QT syndrome and Brugada syndrome disclose evident abnormalities at the basal ECG (long QT interval or ST-segment alteration, respectively), polymorphic ventricular tachycardia does not show any changes in the resting ECG, with premature ventricular beats and ventricular tachycardia usually triggered by increased heart rate during effort. All these conditions are inherited familial ventricular arrhythmias in the setting of structurally intact heart. The genetic background in case of long QT syndrome and Brugada syndrome resides on defective genes coding ion (sodium and potassium) channel proteins regulating myocyte repolarization^{8,11}. As far as polymorphic ventricular tachycardia is concerned, the defect resides on the gene coding cardiac ryanodine receptor 2, which regulates calcium release from the smooth sarcoplasmic reticulum accounting for electromechanical coupling¹⁰. However, nonis-

chemic ST-segment elevation in 90% of cases of our pathologic experience is associated with arrhythmogenic right ventricular cardiomyopathy/dysplasia, a condition clearly associated with a structurally abnormal heart. On the other hand, sodium channel SCN5A gene mutation has been reported also in Lenegre syndrome with atrioventricular block and in Brugada syndrome, associated with PR prolongation and right bundle branch block, all conditions with histopathological substrate at the level of the specialized conducting tissues¹².

The awareness of the existence of sudden cardiac death *sine materia* with a genetic background should alert the pathologist to employ advanced genetic techniques to establish a molecular diagnosis even at *postmortem*, thus reducing the number of cases in which the cause of death remain mysterious.

References

1. Thiene G, Basso C, Corrado D. Cardiovascular causes of sudden death. In: Silver MD, Gotlieb AI, Schoen FJ, eds. Cardiovascular pathology. Philadelphia, PA: Churchill Livingstone, 2001: 326-74.
2. Corrado D, Basso C, Thiene G. Sudden cardiac death in young people with apparently normal heart. Cardiovasc Res 2001; 50: 399-408.
3. Basso C, Calabrese F, Corrado D, Thiene G. Postmortem diagnosis in sudden cardiac death victims: macroscopic, microscopic and molecular findings. Cardiovasc Res 2001; 50: 290-300.
4. Thiene G, Nava A, Corrado D, Rossi L, Pennelli N. Right ventricular cardiomyopathy and sudden death in young people. N Engl J Med 1988; 318: 129-33.
5. Basso C, Thiene G, Corrado D, Angelini A, Nava A, Valente M. Arrhythmogenic right ventricular cardiomyopathy. Dysplasia, dystrophy or myocarditis? Circulation 1996; 94: 983-91.
6. Thiene G, Pennelli N, Rossi L. Cardiac conduction system abnormalities as a possible cause of sudden death in young athletes. Hum Pathol 1983; 14: 704-9.
7. Basso C, Corrado D, Rossi L, Thiene G. Ventricular preexcitation in children and young adults. Atrial myocarditis as a possible trigger of sudden death. Circulation 2001; 103: 269-75.
8. Priori SG, Schwartz PJ, Napolitano C, et al. Risk stratification in the long QT syndrome. N Engl J Med 2003; 348: 1866-74.
9. Corrado D, Basso C, Buja G, Nava A, Rossi L, Thiene G. Right bundle branch block, right precordial ST segment elevation and sudden death in young people. Circulation 2001; 103: 710-7.
10. Bauce B, Rampazzo A, Basso C, et al. Screening for ryanodine receptor type 2 mutations in families with effort-induced polymorphic ventricular arrhythmias and sudden death: early diagnosis of asymptomatic carriers. J Am Coll Cardiol 2002; 40: 341-9.
11. Chen Q, Kirsch GE, Zhang D, et al. Genetic basis and molecular mechanisms for idiopathic ventricular fibrillation. Nature 1998; 392: 293-6.
12. Kyndt F, Probst V, Potet F, et al. Novel SCN5A mutation leading either to isolated cardiac conduction defect or Brugada syndrome in a large French family. Circulation. 2001; 104: 3081-6.

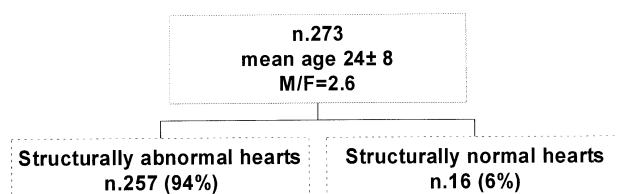


Figure 1. Pathology of sudden cardiac death in the Veneto Region Registry, Padua, Italy

ARRHYTHMIC COMPETITIVE ATHLETES WITH APPARENTLY "INTACT HEART": GENETIC MOLECULAR BASES

Marina Cerrone*, Silvia G. Priori*§

*Molecular Cardiology, IRCCS S. Maugeri Foundation, §University of Pavia, Pavia, Italy

Molecular genetics had recently revealed the mechanisms that underlie some cases of sudden cardiac death in young healthy people. The possibility of performing molecular screening for genetic defects on cardiac ion channels or structural proteins allows to recognize those individuals without structural heart diseases, who are at high risk of ventricular fibrillation and to protect them from life-threatening situations; furthermore it has become possible to identify as silent gene-carriers subjects who are considered "not affected" on clinical ground, but who share a similar risk than those with an "evident" phenotype for such syndromes. The new challenge of molecular cardiology is to use this knowledge to underline differences existing among the genetic variants of each disease and to identify which are the genotype-phenotype correlations that could help in the risk stratification and in the clinical management of patients.

Introduction

In the past years, molecular genetics had entered clinical cardiology, contributing to the identification of specific genetic defects linked to defined clinical syndromes that may predispose the heart to an "electrical imbalance", thus increasing the risk of ventricular fibrillation in healthy and frequently young individuals without structural heart diseases. This short review presents molecular bases of such syndromes, the long QT syndrome (LQTS), the Brugada syndrome (BS) and the catecholaminergic polymorphic ventricular tachycardia (CPVT) and provide some insights about the genotype-phenotype correlations that might help in the risk stratification of these patients.

The long QT syndrome

LQTS is a genetically transmitted disorder characterized by prolonged ventricular repolarization that predispose carriers to life-threatening arrhythmias especially under emotional or physical stress¹. Linkage analysis and mutation screening have demonstrated that this syndrome is caused by defects of ion channels conducting sodium or potassium cardiac currents. Thanks to molecular biology it has been possible classify six different forms of the LQTS: LQT1 and LQT5, due to mutations respectively on the α or the β subunit of the IKs channel; LQT2 and LQT6 due to mutations respectively on the α or β subunit of the IKr channel; LQT3 caused by mutations on the α subunit of the INa channel. The LQT4 variant has been only recently linked to mutations in ankirin-B², a protein that controls Ca²⁺ sig-

naling in cardiomyocytes, but up till now this variant has been described in only one large French family.

All the mutations identified in the genes that encode for potassium ion current result in a reduction in the current (IKs or IKr respectively), thus prolonging the repolarization phase and accounting for the prolongation of the QT interval. Less immediate could be the understanding of how mutations in the sodium current, that is responsible for the depolarization phase, could prolong repolarization. Expression studies clarified that mutations associated to the LQT3 form alter the inactivation process of the channels, so they do not inactivate, but reopen providing the persistence of a small inward current, thus causing the prolongation of the repolarization phase¹.

Clinical studies on LQTS had demonstrated genetic heterogeneity, so molecular biology had not only contributed to clarify the pathogenesis of this disease, but had become a basic tool to make a correct diagnosis. As a matter of fact, LQTS shows a low penetrance in some families, and in these cases, only genetic screening can identify silent gene-carriers with a normal QT duration³. These subjects with a "concealed" form of LQTS are at major risk when some triggering factors as, for example, some drugs that block IKr current or competitive sport, unmask a vulnerable substrate: in such cases, genetics can disclose this substrate allowing to protect silent gene-carriers from life-threatening situations.

Moreover, it has been possible distinguish different clinical features among the three principal variants of LQTS on the basis of the genetic defect⁴. LQT1 patients shorten their QT interval less than normal during exercise and they appear to be at major risk of syncope or cardiac arrest during physical stress, and especially while swimming. On the contrary, LQT3 patients shorten their QT interval during exercise, but show a marked QT prolongation during night or at low heart rate and they experience the most of their cardiac events while sleeping or at rest. LQT2 subjects are more susceptible during emotions and under acoustic stimuli or if their K plasma level is low. If one consider that IKs current is very sensible to catecholamine's effect, it appears comprehensible why LQT1 subjects, who show a defective IKs current, are at risk during adrenergic stress and are the group better protected by beta-blockers. These subjects are at higher risk during exercise than LQT2 and LQT3 patients and they must be discouraged from competitive physical activity. Therefore, the observation that in LQT3 patients the QT interval tends to prolong at low heart rate, could provide an explication for the poor effect of beta-blockers seen in this group. Thus the evidence that different molecular mechanisms underlie these variants justifies the differences seen in clinical manifestations.

Recently, Priori et al.⁵ published a large study on 647 LQTS patients with a known genotype, providing a risk stratification model based also on genotype features. This study demonstrated that QTc duration and genetic locus are independent predictors of a first cardiac event.

The analysis found that the incidence of symptoms was the lowest in the LQT1 group, while the risk to experience cardiac events was higher among LQT2 females and LQT3 male patients.

In conclusion, in the case of LQTS, genetic screening had first contributed to clarify the pathogenesis and the heterogeneity of the disease; therefore in the last period it has been demonstrated that causative mutation can influence the clinical course, thus providing a risk stratification approach based on genotype.

Brugada syndrome

BS is another disease related to mutations on cardiac ion channels, as LQTS, that cause syncope or sudden cardiac death. The peculiar marker of BS is the electrocardiographic pattern of ST-segment elevation in right precordial leads associated with complete or incomplete right bundle branch block⁶. As in the LQTS, this ECG pattern could be concealed and it can be unmasked by a challenge with sodium channel blockers. However, it has been demonstrated⁷ that even the challenge with sodium channel blockers cannot unmask all the gene-carriers with a normal baseline ECG. In such cases, genetic screening will be an important tool to make a diagnosis in those silent gene-carriers lacking the peculiar ECG pattern.

The gene involved in the pathogenesis of BS is the *SCN5A* gene, that encodes for the α subunit of the INa cardiac channel, the same gene that cause LQT3 form. Expression studies have demonstrated that mutations linked to BS phenotype result in a loss of function of the channel⁸. Mutations on *SCN5A* gene account only for 30% of cases with a clinical diagnosis of BS, so even in this case genetic heterogeneity is present. Thus, at this moment it is not possible rule out some genotype-phenotype correlations for BS, and risk stratification is made only on clinical bases. However, a large study on 200 patients affected by BS⁹ has shown that the presence of *SCN5A* mutations is not an independent predictor of sudden cardiac death. Even if genetic screening is able to make diagnosis only on a minor part of affected patients, functional studies on BS-related mutations had provided some interesting insights on a better comprehension of the clinical effects of defective sodium channels. As a matter of facts, one could say that in simple terms BS is caused by defective sodium current and LQT3 by excessive sodium current. However, some groups¹⁰⁻¹² have demonstrated the existence of some mutations that account for intermediate phenotype, that share characteristics of BS, LQT3 and isolated cardiac conduction disease. These finding suggest that the substrate of inherited arrhythmogenic syndromes is more complex than previously thought and that in such cases the effect of a single mutation or of other modifier factors, that will be identified, will play an important role in clinical manifestations of these diseases.

Catecholaminergic polymorphic ventricular tachycardia

Coumel et al.¹³ and Leenhardt et al.¹⁴ first described a disease characterized by the occurrence of stress-related bidirectional ventricular tachycardia (VT) in children and young people with intact heart and without QT interval prolongation. These patients show a normal baseline ECG and developed bidirectional VT under physical or emotional stress in a highly reproducible way. CPVT appear to be a malignant syndrome, as a family history of juvenile sudden cardiac death is present in more than 30% of cases and as the first event occur at an average age of 7-8 years. Bidirectional VT pattern is very similar to the arrhythmic pattern seen during digitalis intoxication, i.e. an arrhythmic mechanism associated with delayed afterdepolarization and calcium overload. Linkage analysis showed a linkage of the disease to the chromosome 1q42-q43 in two families¹⁵. In 2001, Priori et al.¹⁶ demonstrated that the gene responsible for CPVT in four families was the *hRyR2* gene, that encodes for the human cardiac ryanodine receptor. RyR2 is responsible for calcium release from the sarcoplasmic reticulum in response to calcium entry from the voltage-dependent calcium type L-channel. Mutations linked to CPVT are supposed to disrupt the homeostasis of calcium, resulting in increased calcium leak from the sarcoplasmic reticulum during sympathetic stimulation¹⁷. As a matter of fact a diastolic leak of calcium due to a "gain of function" in defective RyR2 could account for the occurrence of delayed afterdepolarization that triggers VT¹⁷. Mutations on *hRyR2* are related to almost 50% of cases of autosomal dominant CPVT, thus genetical heterogeneity has to be considered. Recently, an autosomal recessive variant of CPVT had been linked to a mutation on *CASQ2* gene¹⁸, that encodes for the calsequestrin 2, another protein involved in intracellular calcium homeostasis.

Priori et al.¹⁹ conducted a clinical and molecular screening on 30 patients with CPVT with the aim of underlining the clinical characteristics of the disease and the differences among *hRyR2* mutations carriers and non-carriers. First, the clinical analysis provided the evidence that the diagnosis of CPVT extends beyond the first description made by Coumel et al.¹³ and by Leenhardt et al.¹⁴, as not only patients with bidirectional VT, but also patients with polymorphic VT or catecholaminergic idiopathic ventricular fibrillation belong to this group. Furthermore, genetic analysis identified two groups of patients: non-genotyped CPVT, who are mostly women and tend to become symptomatic in adulthood; *hRyR2*-CPVT patients, who become symptomatic earlier, are predominantly men and show a higher risk of cardiac events. In this case, genetic screening is pivotal to identify the presence of *hRyR2* mutations in male children that are at risk of early onset of symptoms and high malignancy of clinical manifestation of the disease.

Therefore, genetic screening allows to differentiate CPVT from LQTS, another disease with very similar clinical features. This distinction is relevant, in light of the different protection warranted by beta-blockers, that is high in LQTS²⁰, but incomplete in CPVT, as in the study of Priori et al.¹⁹ an implantable cardioverter-defibrillator was required in 30% of patients.

Conclusions

The Centers for Disease Control demonstrated that sudden cardiac death increase by 10% among young US people between 1989 and 1996²¹. In the past years molecular biology has allowed to understand that "idiopathic ventricular fibrillation" may be caused by inherited syndromes linked to genetic defects on cardiac ion channels. Identification of the substrate responsible for these diseases has allowed pre-symptomatic screening in siblings of families known for history of sudden cardiac death. This become pivotal in the case of a life-threatening disease, like CPVT, LQTS or BS in which the first expression of symptoms may be lethal.

The extension of molecular screening in many families has allowed to outline some genotype-phenotype correlations, that may be helpful in the clinical management of patients.

Furthermore, the knowledge of the molecular mechanisms that underlie these syndromes could become a paradigm to a better understanding of the molecular mechanisms involved in arrhythmogenesis, even in other major heart diseases, such as heart failure or coronary artery disease.

References

- Schwartz PJ, Priori SG, Napolitano C. The long QT syndrome. In: Zipes DP, Jalife J, eds. Cardiac electrophysiology: from cell to bedside. 3rd edition. Philadelphia, PA: WB Saunders, 2000: 597-615.
- Mohler PJ, Schott JJ, Gramolini AO, et al. Ankirin-B mutation causes type 4 long QT cardiac arrhythmia and sudden cardiac death. *Nature*, 2003; 421: 634-9.
- Priori SG, Napolitano C, Schwartz PJ. Low penetrance in the long QT syndrome. Clinical impact. *Circulation* 1999; 99: 529-33.
- Schwartz PJ, Priori SG, Spazzolini C, et al. Genotype-phenotype correlation in the long QT syndrome. Gene-specific triggers for life-threatening arrhythmias. *Circulation* 2001; 103: 89-95.
- Priori SG, Schwartz PJ, Napolitano C, et al. Risk stratification in the long QT syndrome. *N Engl J Med* 2003; 348: 1866-74.
- Brugada J, Brugada R, Brugada P. Right bundle branch block and ST segment elevation in leads V1-V3: a marker of sudden death in patients with no demonstrable structural heart disease. *Circulation* 1998; 97: 457-60.
- Priori SG, Napolitano C, Gasparini M, et al. Clinical and genetic heterogeneity of right bundle branch block and ST segment elevation syndrome. A prospective evaluation of 52 families. *Circulation* 2000; 102: 945-7.
- Chen Q, Kirsch GE, Zhang D, et al. Genetic basis and molecular mechanism for idiopathic ventricular fibrillation. *Nature* 1998; 392: 293-6.
- Priori SG, Napolitano C, Gasparini M, et al. Natural history of Brugada syndrome. Insights for risk stratification and management. *Circulation* 2002; 105: 1342-7.
- Bezzina C, Veldkamp MW, van Den Bergh MP, et al. A single Na⁺ channel mutation causing both long QT and Brugada syndromes. *Circ Res* 1999; 85: 1206-13.
- Rivolta I, Abriel H, Tateyama M, et al. Inherited Brugada and LQT3 syndrome mutations of a single residue of the cardiac sodium channel confer distinct channel and clinical phenotypes. *J Biol Chem* 2001; 276: 30623-30.
- Grant AO, Carboni MP, Neplioueva V, et al. Long QT syndrome, Brugada syndrome and conduction system disease are linked to a single channel mutation. *J Clin Invest* 2002; 110: 1201-9.
- Coumel P, Fidelle J, Lucet V, et al. Catecholaminergic-induced severe ventricular arrhythmias with Adam-Stokes syndrome in children: report of four cases. *Br Heart J* 1978; 40 (Suppl): 28-37.
- Leenhardt A, Lucet V, Denjoy I, et al. Catecholaminergic polymorphic ventricular tachycardia in children: a 7-year follow-up of 21 patients. *Circulation* 1995; 91: 1512-9.
- Swan H, Piippo K, Viitasalo M, et al. Arrhythmic disorder mapped to chromosome 1q42-q43 causes malignant polymorphic ventricular tachycardia in structurally normal hearts. *J Am Coll Cardiol* 1999; 34: 2035-42.
- Priori SG, Napolitano C, Tiso N, et al. Mutations in the cardiac ryanodine receptor gene (hRyR2) underlie catecholaminergic polymorphic ventricular tachycardia. *Circulation* 2001; 103: 196-200.
- Marks AR, Priori SG, Memmi M, et al. Involvement of the cardiac ryanodine receptor/calcium release channel in catecholaminergic polymorphic ventricular tachycardia. *J Cell Physiol* 2002; 190: 1-6.
- Lahat H, Pras E, Olender T, et al. A missense mutation in a highly conserved region of CASQ2 is associated with autosomal recessive catecholamine-induced polymorphic ventricular tachycardia in Bedouin family from Israel. *Am J Hum Genet* 2001; 69: 1378-84.
- Priori SG, Napolitano C, Memmi M, et al. Clinical and molecular characterization of patients with catecholaminergic polymorphic ventricular tachycardia. *Circulation* 2002; 106: 69-74.
- Moss AJ, Zareba W, Hall WJ, et al. Effectiveness and limitations of beta-blocker therapy in congenital long QT syndrome. *Circulation* 2000; 101: 616-23.
- Spurgeon D. Sudden cardiac deaths rise 10% in young Americans. (abstr) *BMJ* 2001; 322: 573.

ARRHYTHMIC COMPETITIVE ATHLETES WITH APPARENTLY "INTACT HEART": SILENT MYOCARDITIS

Cristina Basso

Institute of Pathology, University of Padua Medical School, Padua, Italy

A cardiac organic substrate frequently underlies sudden cardiac death, even in the young and in the athlete. Despite careful clinical evaluation, subtle lesions such as focal cardiomyopathy and myocarditis may be under-

recognized. In other words, these diseases are frequently concealed and discovered with surprise only at *post-mortem* examination by means of a thorough macroscopic and histological investigation. In particular, we will address the current knowledge of inflammatory heart muscle disease (myocarditis), ranging from clinical presentation to molecular pathology aspects.

Definition, clinical presentation, and *in vivo* diagnosis

According to the WHO/ISFC classification of cardiomyopathies, "myocarditis is an inflammatory heart muscle disease associated with cardiac dysfunction and is diagnosed by established histological, immunological, and immunohistochemical criteria"¹. Classification may be based on etiological criteria (infective or non-infective myocarditis, whether isolated or in the setting of systemic inflammation), temporal (acute, fulminant, rapidly progressive, chronic, or persistent)^{2,3}, clinical (active, borderline, ongoing, resolving, resolved), or histological (lymphocytic, eosinophilic, polymorphous, granulomatous, giant cell)⁴. The superiority of an etiological classification as far as therapeutic implications are concerned is obvious.

Many open questions still exist regarding myocarditis. Clinical criteria of diagnosis are aspecific, since myocarditis may have disparate clinical presentations including chest pain, infarct-like necrosis, arrhythmias, congestive heart failure, cardiogenic shock, or even sudden, unexpected cardiac arrest in previously asymptomatic subjects. Titers of antiviral antibodies lack significance and are not of help; cultures are also not reliable. The diagnosis is based on histology of the myocardium, which is now feasible also *in vivo*, thanks to the introduction of endomyocardial biopsy in clinical practice⁵. The diagnostic criteria, based on the observation of inflammatory infiltrates in association with myocyte degeneration-necrosis in routine stains, are currently reinforced by the use of immunohistochemistry, which allows precise identification and quantitation of leucocytes-macrophages, not only in acute but also in chronic phases⁶. Unfortunately, the microscopic observation of inflammatory infiltrates does not allow determination of the infectious, immune, or idiopathic nature of myocarditis. Thanks to the advent of molecular biology techniques, such as polymerase chain reaction (PCR) and *in situ* hybridization, it is now possible to systematically investigate the presence of viral genome in the myocardium in order to establish the precise etiology of the disease, set up targeted therapeutic strategies, and predict the course or recurrence of the inflammatory disease. Viral myocarditis, indeed, should be approached from the therapeutic standpoint with antiviral drugs, leaving immunosuppressive therapy to idiopathic or immune forms. Thus, the use of molecular diagnosis should be the gold standard not only for diagnosis but also for proper therapy⁷.

Myocarditis and sudden death in the young

Based on the Veneto Region study project findings on juvenile (35 years) sudden death, the most common causes include premature coronary atherosclerosis (21%), arrhythmogenic right ventricular cardiomyopathy (14%), mitral valve prolapse (12%), non-atherosclerotic coronary artery disease (11%), myocarditis (10%), conduction system disease (9%) and hypertrophic cardiomyopathy (7%).

Myocarditis is one of the most common causes of sudden death in the young and adolescents⁸⁻¹⁶ ranking first in the series of Topaz and Edwards⁹, comprising 12 cases (24%), of which 11 were presumed to be viral and one sarcoid. It is noteworthy that among the cases of acute myocarditis was a 9-year-old boy with mumps who died suddenly on the third day of illness.

A major limitation in the autopsy diagnosis of myocarditis in several series has been the lack of standardized histological criteria. The strongest evidence that subclinical myocarditis can be a cause of ventricular fibrillation comes from an autopsy series on United States Army recruits in which 42% of those who died suddenly had histological evidence of myocarditis¹⁴. Although myocarditis usually presents with signs of pump failure and ventricular dilation, ventricular arrhythmias have been described in patients with myocarditis and an apparently normal heart. A recent flu-like illness is common, although the symptoms may be mild and clinical signs of heart failure subtle or absent. Cardiac involvement is unpredictable and may affect the conduction system, causing heart block, or the ordinary myocardium, causing ventricular arrhythmias. Sometimes the patients suffer previous syncopal episodes and/or palpitations. The electrocardiogram may show diffuse low voltage, ST-T changes, and often heart block or ventricular arrhythmias. Sudden death may occur both in the active or healed phases as a consequence of life-threatening ventricular arrhythmias that develop mostly in the setting of an unstable myocardial substrate, namely inflammatory infiltrate, interstitial edema, myocardial necrosis, and fibrosis. The gross appearance of the heart is not distinctive and its weight may be within normal values. Histology invariably discloses either a "starry-like sky" feature (> 14 leucocytes/mm²) or patchy inflammatory infiltrate, sometimes no more than 3 foci at magnification 6 \times , and not necessarily associated with myocyte necrosis. This subtle substrate, together with the possible inflammatory involvement of the conduction system, seems highly arrhythmogenic and may account for unexpected arrhythmic cardiac arrest¹⁷. The inflammatory infiltrates are usually polymorphous and less frequently purely lymphocytic. Sudden death due to patchy giant cell myocarditis as well as eosinophilic myocarditis in the setting of an allergic condition, have also been reported. Rheumatic carditis is currently an exceptional occurrence.

Evidence of myocardial infection, whether bacterial or viral, has rarely been found. *Chlamydia pneumoniae* myocarditis was implicated in the sudden deaths of several young Swedish elite orienteers after RNA from this organism was detected in the heart of one of the victims¹⁸. A subsequent paper implicated this agent in one third of sudden cardiac deaths of the 15 Swedish orienteers who died unexpectedly between 1979 and 1992¹⁹. Awareness of the problem and modification of "training habits and attitudes" have been effective, since no further deaths in the following years have been reported among Swedish orienteers.

Nonetheless, viral infections are the most plausible cause. Application of gene amplification techniques is particularly useful in detecting viral nucleic acids in biopsies, especially when characteristic cytopathic changes cannot be observed on light microscopy, a rather frequent condition in acute fatal forms causing sudden death. Although enterovirus is the most important causative agent in the pathogenesis of myocarditis, several studies have shown that various other viruses, such as adenovirus, herpes virus (cytomegalovirus, herpes simplex virus, Epstein-Barr virus), parvovirus, influenza virus A or B, and hepatitis C virus can be involved in myocardial infective disease, particularly in the pediatric population. As far as the issue of an *in vivo* diagnosis of myocarditis, endomyocardial biopsy plays a key role²⁰⁻²³. To increase diagnostic sensitivity, use of immunohistochemistry is mandatory to identify and characterize the inflammatory infiltrate. Immunohistochemical analysis must always be carried out by means of CD45 (leukocyte antigen common), CD43 (T-lymphocytes), CD45RO (activated T-lymphocytes), CD68 (macrophages), CD20 (B-lymphocytes), CD4 (T-helper), and CD8 (cytotoxic T-lymphocytes) monoclonal and polyclonal antibodies.

Furthermore, classic morphology rarely identifies the etiological agent. The diagnosis of viral myocarditis for a long time had been based on viral culture and serology. However, these investigations are time-consuming and generally fall short in specificity and sensitivity. More recently, molecular biology techniques such as PCR and nested-PCR have been shown to rapidly detect the presence of infective agents, in a specific and very sensitive way, also using a very small amount of tissue such as the fragments of endomyocardial biopsies⁷. To obtain a specific molecular diagnosis of infective myocarditis, whole blood or serum is routinely analyzed to exclude "blood contamination". Different molecular strategies are now used to detect infective status of viruses: in fact, reverse transcriptase-PCR is usually performed instead of PCR to detect specific mRNA indicative of active viral replication and not only the presence of a latent viral form. Moreover, molecular biology techniques are successfully applied to better understand the pathogenesis of myocarditis.

Studies in laboratory animals with myocarditis have shown a significant increase in mortality with strenuous

physical activity^{24,25}. In particular, exercise during the acute phase of the disease leads to increased viral replication, more extensive myocyte necrosis, and a worse chance of survival. Phillips et al.¹⁴ reported that exertion may have been a precipitating factor in Air Force recruits who died due to myocarditis. In the Veneto Region experience, myocarditis accounted for 6% of fatalities among competitive athletes¹⁰. The ventricular fibrous repair following inflammatory injury may create an arrhythmogenic *milieu* that could be unmasked with exercise. The Bethesda conference²⁶ on athletes with cardiovascular disorders recommended a convalescence period of 6 months after the onset of symptoms. Athletic participation depends on the ventricular function as assessed by echocardiography, as well as the absence of clinically significant arrhythmias.

Finally, drug-related myocarditis should always be taken in mind when approaching myocarditis as a cause of cardiac arrest in the young, particularly in athletes. It may be due to a direct dose-related toxic effect or may be secondary to a hypersensitivity reaction, which may occur any time during the course of therapy. For instance, in autopsy studies of patients who died from cocaine intoxication, a mononuclear infiltrate with foci of necrosis has been noted as a prominent finding²⁷. Moreover, even anabolic steroid abuse and cardiac death due to myocarditis has been reported²⁸.

References

1. Richardson P, McKenna WJ, Bristow M, et al. Report of the 1995 WHO/ISFC Task Force on the definition and classification of cardiomyopathies. *Circulation* 1996; 93: 841-2.
2. Fenoglio JJ, Ursell PC, Kellog CF, Drusin RE, Weiss MB. Diagnosis and classification of myocarditis by endomyocardial biopsy. *N Engl J Med* 1983; 398: 12-8.
3. Lieberman EB, Hutchins GM, Herskowitz A, Rose NR, Baughman KL. Clinicopathologic description of myocarditis. *J Am Coll Cardiol* 1991; 18: 1617-26.
4. Aretz HT, Billingham ME, Edwards WD, et al. Myocarditis: the Dallas criteria. *Hum Pathol* 1987; 18: 619-24.
5. Baroldi G, Thiene G. *La biopsia endomiocardica*. Padova: Piccin Editore, 1996.
6. Lindger J, Cassling RS, Rogler WG, et al. Immunohistochemical characterization of lymphocytes in uninflamed ventricular myocardium: implications for myocarditis. *Arch Pathol Lab Med* 1985; 109: 917-20.
7. Calabrese F, Thiene G. Myocarditis and inflammatory cardiomyopathy: microbiological and molecular biological aspects. *Cardiovasc Res* 2003; 60: 11-25.
8. Driscoll DJ, Edwards WD. Sudden unexpected death in children and adolescents. *J Am Coll Cardiol* 1985; 5 (Suppl B): 118B-121B.
9. Topaz O, Edwards JE. Pathologic features of sudden death in children, adolescents, and young adults. *Chest* 1985; 87: 476-82.
10. Corrado D, Basso C, Schiavon M, Thiene G. Screening for hypertrophic cardiomyopathy in young athletes. *N Engl J Med* 1998; 339: 364-9.
11. Liberthson RR. Sudden death from cardiac causes in children and young adults. *N Engl J Med* 1996; 334: 1039-44.

12. Molander N. Sudden natural death in later childhood and adolescence. *Arch Dis Child* 1982; 57: 572-6.
13. Neuspiel DR, Kuller LH. Sudden and unexpected natural death in childhood and adolescence. *JAMA* 1985; 254: 1321-5.
14. Phillips M, Robinowitz M, Higgins JR, et al. Sudden cardiac death in Air Force recruits: a 20-year review. *JAMA* 1986; 256: 2696-9.
15. Kramer MR, Drory Y, Lev B. Sudden death in young Israeli soldiers: analysis of 83 cases. *Isr J Med Sci* 1989; 25: 620-4.
16. Drory Y, Turetz Y, Hiss Y, et al. Sudden unexpected death in persons less than 30 years of age. *Am J Cardiol* 1991; 68: 1388-92.
17. Basso C, Calabrese F, Corrado D, Thiene G. Postmortem diagnosis in sudden cardiac death victims: macroscopic, microscopic and molecular findings. *Cardiovasc Res* 2001; 50: 290-330.
18. Wesslen L, Pahlson C, Friman G. Myocarditis caused by Chlamydia pneumoniae (TWAR) and sudden unexpected death in a Swedish elite orienteer. *Lancet* 1992; 240: 427-8.
19. Wesslen L, Pahlson C, Lindquist O, et al. An increase in sudden unexpected cardiac deaths among young Swedish orienteers during 1979-1992. *Eur Heart J* 1996; 17: 902-10.
20. Tazelaar HD, Billingham ME. Myocardial lymphocytes: fact, fancy or myocarditis? *Am J Cardiovasc Pathol* 1987; 1: 47-50.
21. Hauck AJ, Kearney DL, Edwards W. Evaluation of post-mortem endomyocardial biopsy specimens from 38 patients with lymphocytic myocarditis: implications for role of sampling error. *Mayo Clin Proc* 1989; 64: 1235-45.
22. Chow LH, Radio SJ, Sears TD, McManus B. Insensitivity of right ventricular endomyocardial biopsy in the diagnosis of myocarditis. *J Am Coll Cardiol* 1989; 14: 915-20.
23. Shirani J, Freant LJ, Roberts WC. Gross and semiquantitative histologic findings in mononuclear cells myocarditis causing sudden death and implications for endomyocardial biopsy. *Am J Cardiol* 1993; 72: 952-7.
24. Graimantian B, Chason J, Lerner A. Augmentation of the virulence of murine coxsackie B3 myocardiopathy by exercise. *J Exp Med* 1970; 131: 1121-36.
25. Zeppilli P, Santini C, Palieri V, et al. Role of myocarditis in athletes with minor arrhythmias and/or echocardiographic abnormalities. *Chest* 1994; 106: 373-80.
26. Maron BJ, Mitchell JH. 26th Bethesda Conference: recommendations for detecting eligibility for competition in athletes with cardiovascular abnormalities. *J Am Coll Cardiol* 1994; 24: 845-99.
27. Virmani R, Robinowitz M, Smialek J, Smyth D. Cardiovascular effects of cocaine: an autopsy study of 40 patients. *Am Heart J* 1988; 115: 1068-75.
28. Kennedy MC, Lawrence C. Anabolic steroid abuse and cardiac death. *Med J Aust* 1993; 158: 346-8.

ARRHYTHMIC ELITE ATHLETES WITH APPARENTLY "INTACT HEART"

Francesco Furlanello, Annalisa Bertoldi*,
Francesco Terrasi**, Riccardo Cappato

Center of Clinical Arrhythmology and Electrophysiology, Istituto Policlinico San Donato, University of Milan, San Donato Milanese (MI), *Department of Cardiology, S. Chiara Hospital, Trento, **Villa Bianca Hospital, Trento, Italy

Background. Elite athletes are considered by the public the epitome of health with a normal heart. It is, however, not a rare finding to observe during a sport career several types of arrhythmias which in some cases can be life-threatening and can lead to major events as an arrhythmic syncope, cardiac arrest and sudden death. There is also evidence to suggest that athletic activity can have a trigger effect in the induction of pathological arrhythmias in athletes with silent underlying arrhythmogenic pathologies, as well as to induce a clinical "acceleration" of many types of latent arrhythmogenic structural heart diseases, or of primary electrical disorders. In our 29-year experience we found that about 20% of arrhythmic elite athletes with significant arrhythmias may have an apparently "intact heart" also after extensive non-invasive and invasive examination. The purpose of this study is to refer on the clinical aspects and outcome of a subgroup of elite athletes with severe rapid clinical and induced ventricular tachycardia (VT) without an overt heart disease.

Methods. Since 1974 we have continuously evaluated competitive athletes performing different types of sports, and referred to us for arrhythmias. All these athletes underwent an individualized risk assessment by arrhythmologic investigation, with a study protocol including non-invasive and invasive diagnostic techniques. For individual athletes the risk assessment, if necessary, included family and personal history, clinical visit, blood tests (including thyroid function tests), resting and stress test ECG, Holter recording (also during intense physical activity), two Doppler color flow echocardiography, pharmacological and during exercise stress echo, transesophageal echocardiography, magnetic resonance imaging, nuclear cardiology, signal-averaged ECG, head-up tilt-test, specific blood test (i.e. for myocarditis), microvolt T-wave alternans, pharmacological testing (flecainide administration, isoproterenol infusion), genetic studies, endocavitary electrophysiologic study, cardiac catheterization and angiography, endomyocardial biopsy.

Results. In June 2003 the population of this study consisted of 2503 young (< 36 years) competitive athletes (2160 males and 343 females), with an average age of 21.7 years, with a follow-up ranging from 3 months to over 12 years. In this group 285 elite athletes were included (248 males, 37 females); with an average age of 24.2 years, and follow-up ranging from 3 months to just over 10 years; all the considered subjects had previously been competing at international level, including World, Olympic, European and National Championships. A subgroup of 12/285 (4.2%) elite athletes, 10 males, mean age 25.2, follow-up ranging from 11 to 108 months, had more episodes of rapid symptomatic sustained VT frequently effort-related. VT was right in all, with multiple VT morphologies in 6. VT was reinduced by electrophysiologic study in all subjects, degenerating in ventricular fibrillation or in an hemodynamically unstable VT in 7. In these elite athletes, Brugada

syndrome, catecholaminergic polymorphic VT and illicit drug assumption were excluded. Genetic studies were performed in 6/12, with negative results. A cardioverter-defibrillator was implanted in 4 with discharges in all (the first discharge ranging from 2 to 14 months after implantation). Radiofrequency catheter ablation with electromechanical mapping was performed in 6, in one with epicardial approach. A myocarditis was documented in 1/12 elite athlete (lymphocytic) and in 2/12 was suspected. An arrhythmogenic right ventricular dysplasia was suspected but not documented in 5 elite athletes. Minor right ventricular wall abnormalities were detected in 7 with imaging techniques (echocardiography, magnetic resonance imaging, right ventricular angiography) and were stable during follow-up. All subjects are alive, under antiarrhythmic drug treat-

ment. Two elite athletes with healed myocarditis are alive without antiarrhythmic drug treatment.

Conclusion. Clinical and inducible severe life-threatening VT are possible in elite athletes with apparently intact heart and probably micropathology, who were examined many times along the follow-up. Only minor cardiac abnormalities with current imaging technique were found including the subjects with documented or suspected myocarditis or arrhythmogenic right ventricular dysplasia. The use of electroanatomical voltage mapping during electrophysiologic study and radiofrequency catheter ablation was useful to define the presence of an arrhythmogenic abnormal myocardial zone. For this kind of arrhythmic athletes at high risk of cardiac arrest and sudden death, a careful clinical surveillance during the outcome is mandatory.